MAHKOTA MEDICAL CENTRE 仁愛医院

REGENCY SPECIALIST HOSPITAL 立康医院

長庚紀念醫院 Chang Gung Memorial Hospital

THE MANAGEMENT STRATEGIES IN **ENDOMETRIOSIS & ADENOMYOSIS SPECTRUM**

VIRTUAL CONFERENCE
2 October 2021, Saturday

AUGUST 2021

WELCOME TO THE MANAGEMENT STRATEGIES IN **ENDOMETRIOSIS & ADENOMYOSIS** SPECTRUM VIRTUAL CONFERENCE 2021...

DR. SHARIFAH HALIMAH JAAFAR

SENIOR CONSULTANT
OBSTETRICS & GYNAECOLOGY,
MIS SURGEON, REGENCY SPECIALIST HOSPITAL

ORGANIZING COMMITTEE ADVISOR

Endometriosis and adenomyosis are both painful and chronic inflammatory diseases that can be lifelong suffering to many women until they reach menopause. The chronicity of the disease does not only caused a significant impact to women's quality of life and their productivity during their prime years but often than not poses a great challenge to doctors to effectively manage the disease manifestation, and in keeping the patient symptom free and functional for a long period of time.

Thus, **The Management Strategies In Endometriosis & Adenomyosis Spectrum Virtual Conference 2021**, is specially designed with aim to bring greater understanding of the disease and its management from medical perspective and surgically in particular minimally invasive surgery. It is a full day course with lectures, near live or prerecorded operative demonstration and discussion with our local and international experts.

On behalf of the organizing committee, I would like to invite and welcome you to participate in this interesting event and to learn from the comfort of your own home.

"Happy Learning!"

AGENDA

0800	**GUESTS LOGIN**
0815	**WELCOME SPEECH BY HMI, MS. CHIN WEI JIA** MANAGING DIRECTOR, HMI GROUP
0830	**THE IMPACT OF ENDOMETRIOSIS & ADENOMYOMA ON QOL & STRATEGY FOR LONG-TERM CARE** DR. SHARIFAH HALIMAH JAAFAR
0915	**ENDOMETRIOSIS IN ADOLESCENTS: DIAGNOSIS, CHALLENGES & MANAGEMENT** ASSOCIATE PROF DR. ANI AMELIA BT DATO ZAINUDDIN
1000	**ULTRASOUND DIAGNOSIS & MANAGEMENT OF INFERTILITY ASSOCIATED WITH ENDOMETRIOSIS** DR. WILLIAM HOO WEE LIAK
1045	**10 MINUTES BREAK**
1055	**MANAGEMENT OF PAIN IN ENDOMETRIOSIS, DYSMENORRHEOA AND CHRONIC PELVIC PAIN** ASSOCIATE PROF DR. SUSAN EVANS
1140	**ENDOMETRIOSIS ASSOCIATED MALIGNANT TRANSFORMATION** DR. BADRUL ZAMAN BIN MUDA
1225	**FORUM ON CASE STUDIES / Q&A** ALL SPEAKERS

1300 **LUNCH BREAK**

1400 **LAPAROSCOPIC MANAGEMENT OF ENDOMETRIOSIS & OVARIAN ENDOMETRIOMA**
DR. CHUA PENG TENG

1445 **DIAGNOSIS & LAPAROSCOPIC MANAGEMENT OF DEEPLY INFILTRATING ENDOMETRIOSIS**
DR. YEN, CHI-FENG

1530 **10 MINUTES BREAK**

1540 **HIFU: A NEW HOPE IN THE MANAGEMENT OF ADENOMYOSIS**
DR. SEVELLARAJA SUPERMANIAM

1625 **ADENOMYOSIS & LAPAROSCOPIC ADENOMYOMECTOMY**
DR. YEN CHIH-FENG

1710 **LUCKY DRAW**

1730 **DISMISS**

Hands That Treat Heart That Heal

MS SERENA YONG

CHIEF EXECUTIVE OFFICER
REGENCY SPECIALIST HOSPITAL

Greetings from Regency Specialist Hospital. I would like to extend to you a very Warm Regency welcome. Thank you very much for your participation in our inaugural **The Management Strategies In Endometriosis & Adenomyosis Spectrum Virtual Conference 2021.**

I am proud to celebrate this day of honour for all the world's women and all the progress that has been made over the past century. We also acknowledge that the health, safety and wellbeing of women is paramount, and this is especially true as we continue in this battle against COVID-19.

On behalf of Regency and all the strategic partners who have make this conference a great success, I would like to thank all the participants for your undivided commitment, dedication and continuously pushed the boundaries in maintaining a consistently high standards in delivering quality care in women's health.

Ultimately, my heartfelt gratitude to all honourable speakers. Your great contributions to this virtual conference are the reflections of Hand that Treat, Hearts that heal.

Thank you.

DR. SHARIFAH HALIMAH JAAFAR

SENIOR CONSULTANT OBSTETRICS & GYNAECOLOGY, MIS SURGEON, REGENCY SPECIALIST HOSPITAL

Dr Sharifah Halimah Jaafar, a senior consultant obstetrician & gynaecologist with more than 25 years of experience in managing extensive ranges of gynaecological diseases and women's health issues from simple to complex cases. Dr Sharifah Halimah also an accomplished and highly skilled surgeon in performing core and specialised procedures in obstetrics & gynaecology field especially in advanced laparoscopic gynaecological surgery of various indications.

She received her primary medical degree (M.D) from UKM in 1991 and completed her Master Degree of Medicine in Obstetrics & Gynaecology from UKM in 2001. She started to learn operative laparoscopy back from year 2003 and received a hand-on training in minimally invasive surgery from many renounced laparoscopic experts locally and internationally as well as hands-on advanced gynae-laparoscopic course in IRCARD Centre, Taiwan. She completed the accredited ISGE course of Bachelor in Minimally Invasive Surgery (MIGS) from International Society of Gynae-Endoscopy in 2018. She is currently a chairperson for OGSM Gynae-Endoscopic Subcommittee for 2021/2022. Apart from minimally invasive surgery Dr Sharifah also has had received a hands-on training in Fertility & IVF from CREST Centre, Vietnam in 2014.

Dr Sharifah also has special interest in Aesthetic Gynaecology and has obtained a Letter of Credentialing and Privileging in Aesthetic Medicine in 2015 and a board-certified aesthetic practitioner by American Academy of Aesthetic Medicine (AAAM, USA).

On research and publication, Dr Sharifah Halimah has authored and contributed many reviews to Cochrane Collaboration Database in area of Pregnancy & Childbirth and Menstrual Disorders.

On personal level, Dr Sharifah is very friendly and readily approachable by her patients as she believes every woman deserves a dedicated and compassionate.

THE IMPACT OF ENDOMETRIOSIS & ADENOMYOMA ON QUALITY OF LIFE (QoL) & STRATEGY FOR LONG-TERM CARE

Endometriosis and adenomyosis are both oestrogen dependent disease with chronic pain as a hallmark symptom. It both affecting 10% of women of reproductive age being endometriosis is more commonly seen in younger age women and adenomyosis is in slightly older women. It may be asymptomatic or could include clinical manifestations such as chronic pelvic pain, dysmenorrhea, dyspareunia, dysuria, pain after the menstrual period, and infertility.

Endometriosis occurs in women in the reproductive phase with a high incidence, and worsens their quality of life (QoL), causing discomfort, psychic, physiological, marital, and social liability. It is a disease that can lead to social isolation; and such behavior may be related to pain and fatigue that also trigger psychological alterations; loss of productivity at work; whilst its recurrence has the greatest negative impact on psychological health, vitality, financial conditions, and reduction in social activities.

Due to the chronicity of the diseases, it may be associated with considerable physical and emotional morbidity; and it is also known that sufferers experience harm in their daily activities, which has an economic impact due to a reduction or loss of working hours and hospitalizations.

The treatment does not necessarily guarantee a cure or complete remission of symptoms but may only contribute to improving the patients' quality of life. Long term care and effective strategy for pain symptom control is a paramount important in the management.

ASSOCIATE PROF DR. ANI AMELIA BT DATO ZAINUDDIN

CONSULTANT IN PAEDIATRIC & ADOLESCENT GYNAECOLOGY, DEPT OBSTETRICS & GYNAECOLOGY, HOSPITAL CANSELOR TUANKU MUHRIZ (HCTM) UKM

Associate Prof Dr. Ani Amelia Dato' Zainuddin is a Consultant Obstetrician & Gynaecologist in Hospital Tunku Mukhriz Universiti Kebangsaan Malaysia (HCTM UKM), specializing in Paediatric & Adolescent Gynaecology (PAG).

She is a Fellow of the International Federation of Infant and Juvenile Gynaecology (FIGIJ) and the Head of the PAG Unit in HCTM UKM. She and her colleague, Prof. Nur Azurah Abdul Ghani, established the first PAG unit in Malaysia in 2008. They receive referrals from all over Malaysia, where they manage girls and young women with O&G problems.

She has conducted research in PAG, published and presented in national and international congresses. Her special interest is in managing patients with Disorders / Differences of Sex Development (DSD), patients with Premature Ovarian Insufficiency (POI) and Islamic perspectives in managing gender issues in patients with DSD. The PAG Unit in HCTM UKM has been accredited as an international training centre for PAG by FIGIJ.

ENDOMETRIOSIS IN ADOLESCENTS: DIAGNOSIS, CHALLENGES & MANAGEMENT

Endometriosis may not be as uncommon as originally thought in adolescents. A recent systematic review reported that the majority of adolescent girls with chronic pelvic pain not responding to medical therapy have endometriosis, as high as 80%. Obstructive Mullerian anomalies also contribute to causing endometriosis in adolescents. There is often a delay of many years in the diagnosis, up to 12 years. There are unique challenges in making the diagnosis and in the management of this condition in adolescents. They are more likely to present with noncyclical pelvic pain and are referred to different medical disciplines before they reach the gyanecologist.

For those with no obstructive genital tract anomalies, the endometriotic lesions during laparoscopies in adolescents are different in appearance from adults. These are the likely reasons for delay in the diagnosis. This results in a delay in treatment which negatively impacts the functionality and future fertility of the young girls. It affects their school attendance and performance and affects their quality of life. The recent literature advocates for surgical therapy in the management rather than just medical.

Although endometriosis is an estrogen-dependent disease, the effectiveness of suppressive hormonal agents in the prevention of disease progression and development of long-term sequelae such as infertility remains debatable.

DR. WILLIAM HOO WEE LIAK

CONSULTANT OBSTETRICS & GYNAECOLOGY, SUBSPECIALIST IN REPRODUCTIVE MEDICINE, HOSPITAL KENSINGTON GREEN SPECIALIST CENTRE

Dr William Hoo is a Consultant Gynaecologist, Specialist in Reproductive Medicine and Advanced Minimal Access Surgeon at Kensington Green Specialist Centre in Johor, Malaysia. He is the lead for the IVF Centre in this hospital.

Dr Hoo graduated from King's College London, United Kingdom (UK) in 2002 with preclinical Merits. He completed his specialty training in London and became a member of the Royal College of Obstetrician and Gynaecologist (RCOG) in 2012. He was awarded his Doctorate degree, MD(Res), by University College London for his thesis on Endometriosis.

He was selected for the RCOG Advanced Minimal Access Training in 2011, bestowed to the top five candidates in the UK each year. He was also awarded the British Society for Gynaecological Endoscopy (BSGE) 'Clinical Expertise Programme' and a Fellowship to Milwaukee, USA to advance his surgical skills.

In fertility, Dr Hoo has completed both the RCOG Advanced Training Specialist Module (ATSM) and British Fertility Society accreditations. He was appointed a Consultant Fertility Subspecialist & Minimal Access Surgeon at King's College Hospital, his alma mater, before returning to his home country in 2019. King's Fertility has been at the forefront of fertility treatment since 1983 and completes over 1,500 IVF cycles each year.

He has written book chapters, published over two dozen peer-reviewed academic papers and accumulated over 1,000 publication citations. He is passionate about tailoring treatments to meet the unique and specific needs of his patients.

ULTRASOUND DIAGNOSIS & MANAGEMENT OF INFERTILITY ASSOCIATED WITH ENDOMETRIOSIS

Endometriosis is a common gynaecological problem, affecting approximately 5% of women and the disease can be found in many sites throughout the pelvis, in particular the ovaries, pouch of Douglas (POD), rectosigmoid, rectovaginal septum (RVS), uterosacral ligaments.

Correct site-specific diagnosis is fundamental in defining the optimal treatment strategy for endometriosis. In expert hands, transvaginal ultrasound allows us to accurately map the location and extent of endometriotic lesions.

The IDEA (International Deep Endometriosis Analysis group) statement is a consensus on terms, definitions and measurements that has been suggested to describe the different sonographic features of endometriosis.

Women with endometriosis are confronted with one or both of two major problems, endometriosis associated pain, infertility, or both. The management of infertility associated with endometriosis will also be discussed.

ASSOCIATE PROF. DR. SUSAN EVANS

GYNAECOLOGIST, RESEARCHER, PAIN SPECIALIST & FOUNDER PELVIC PAIN FOUNDATION, ADELAIDE, AUSTRALIA

A/Prof Dr Susan Evans is a renowned gynaecologist, researcher, pain physician and an advanced minimally invasive surgeon for more than 20 years experiences in private practice in Adelaide, Australia. Dr Evans studied Medicine at the University of Tasmania, winning the Surgery Prize in her final year of Medicine. She completed her specialist training in Gynecology in Adelaide. She is a Fellow, Royal Australia New Zealand College of Obstetricians Gynaecologists (FRANZCOG). She is also a clinical Associate Professor, University of Adelaide.

In 2002 Dr Evans become a first female Board Member of Australian Gynaecological Endoscopy Society and she performed about 100 laparoscopies per year during her 20 years practice. In 2005, she authored the book Endometriosis and Pelvic Pain to support women with pain and in she was awarded a fellowship of the Faculty of Pain Medicine, Australia in 2010.

In 2011, Dr Evans co-authored the policy document The $6Billion Woman and the $600Million Girl: The Pelvic Pain Report and thereafter in 2012 she facilitated the formation of a multi-disciplinary endometriosis and pelvic pain clinic. A/Prof Susan Evans saw the difficulties girls and women with pain suffered, and the lack of co-ordinated, effective services to help them. Since then, her work has focused on addressing the wide range of issues that reduce the ability of girls, women and men with pelvic pain to live to their full potential. In 2014, she co-founded the Pelvic Pain Foundation of Australia to provide a peak advocacy body for Australians with pelvic pain. About 3 years later in 2017, Dr Evans founded Alyra Biotech to develop innovative treatments for female pelvic pain and she became member of the Robinson Research Institute Advisory Board. She also co-wrote the Periods, Pain and Endometriosis (PPEP-Talk) Schools Program, to assist teens with pain in Australia in 2018. Of more recent in the year 2021, Dr Evans was awarded PhD for research Investigating the neuroimmune basis of dysmenorrhoea, pelvic pain and endometriosis where she was awarded title of Associate Professor, University of Adelaide.

Currently Dr Evans is a CEO of the Alyra Biotech Ptd Ltd, an Advisory Group Member for Australia's National Endometriosis Action Plan and a Chair of Pelvic Pain Foundation of Australia.

MANAGEMENT OF PAIN IN ENDOMETRIOSIS, DYSMENORRHEOA AND CHRONIC PELVIC PAIN

As gynaecologists, we understand that there is more to being a woman with endometriosis than just the lesions we see at her laparoscopy. She may certainly have dysmenorrhea, but how do additional symptoms such as an irritable bowel, painful bladder, food intolerances, the stabbing pains of pelvic muscle spasm, vulval pain, migraine, fatigue, anxiety, low mood, nausea, dizziness, sweating fit in? Surgery to remove endometriosis lesions is important, but often only part of her path to good health.

This presentation will combine gynaecology, pain medicine, and modern neuroimmune concepts to explain the wide variety of lived pain experiences in women with, and without, endometriosis. It will explain how these symptoms fit together, how to explain these concepts to your patients, and how to manage their symptoms effectively.

Optional Reading:

1. Evans, S.F., T.A. Brooks, A.J. Esterman, Hull Ml, and P.E. Rolan. "The Comorbidities of Dysmenorrhea: A Clinical Survey Comparing Symptom Profile in Women with and without Endometriosis." J Pain Res 11 (2018): 3181–94.
2. A free download for your patients with period or pelvic pain from the Pelvic Pain Foundation of Australia: The Pelvic Pain Booklet https://www.pelvicpain.org.au/category/for-women/?v=ef10366317f4
3. In-depth research into the neuroimmune links between dysmenorrhoea, chronic pelvic pain and endometriosis: Investigations into the lived experience and aetiology of dysmenorrhoea and pelvic pain in young women https://digital.library.adelaide.edu.au/dspace/handle/2440/130106

DR. BADRUL ZAMAN BIN MUDA

CONSULTANT GYNAE-ONCOLOGIST, REGENCY SPECIALIST HOSPITAL

Dr Badrul completed his undergraduate (MBBS) degree in 1998 and further post-graduate qualifications MRCOG (UK) under British Council Sponsorship programme in 2004, at West Wales General Hospital , Wales ,UK. He returned to Malaysia in 2006 and later completed his fellowship training in GynaeOncology (FGO) Ministry of Health, Malaysia.

He has served at various state hospitals under Ministry of Health , Malaysia for 21 years before joining Regency Specialist Hospital in 2018 and visiting consultation to Mahkota Medical Centre.Dr Badrul was conferred Fellowship, (FRCOG) by Royal College of Obstetricians & Gynaecologist , London in 2017 and is also a certified Gynaecology SOTM (Science of Tissue of Management) trainer (Ethicon J&J Company) since 2015.He is a council member of Malaysian Gynaecological Cancer Society and recently appointed by the President, Malaysian Medical Council for the approval board subcommittee for GynaeOncology ,National Specialist Registry, Academy of Medicine,Malaysia 2021.

His academic activities includes appointed honorary Senior Clinical Lecturer posts (Newcastle University Medicine Malaysia , Nusajaya 2014 - 2018 , Monash Medical University ,Johor Bahru 2020 -2021) , Centre of Clinic Research , CRC 2014- 2018 , and primary site investigator for local and international gynaeoncological research studies. He is part of the technical committee of Royal Tunku Laksamana Johor Cancer Foundation, Johor Bahru , and provides local and international health talks and publications to public and doctors alike.

ENDOMETRIOSIS ASSOCIATED MALIGNANT TRANSFORMATION

Endometriosis is estimated to be present in 2%–10% of women in the reproductive age group and up to 30% of infertile women. Epidemiologic, histopathologic, and molecular data suggest endometriosis may be a precursor lesion to specific subtypes of ovarian cancer , particularly type 1 epithelial ovarian cancer (endometrioid, clear cell, mucinous, and micropapillary serous carcinomas and low-grade serous carcinomas) comprising 25% of all ovarian cancer. Sampson's criteria and additional Scotts criteria has been the basis for diagnosing carcinoma in the background of endometriosis.

Ovarian Cancer Association Consortium data suggest that women with endometriosis had a significantly higher risk of developing ovarian cancer than the general population (odds ratio [OR] 1.46, 95% confidence interval [CI] 1.31– 1.63; P<.0001). Also, theres a significant association between preexisting endometriosis and low-grade serous invasive ovarian cancers (OR 2.21; P < 0.0001), but not high grade serous and mucinous carcinomas.Risk factors include obesity with endometriosis, prolonged estrogen exposure , presence of histological atypical endometriosis tissue ,endometriosis at an early age and with infertility association.No substantial screening modalities exist as yet for ovarian cancer.

Management would be tailored to individual circumstances , with focus on whether oncofertility is desired or one has completed her family, emphasizing on bilateral salpingectomy and macroscopic resection of all endometriotic tissues.Early stage and grade of endometriod carcinoma and estrogen receptor positive neoplasms carry good 5 years survival rate .

Search: endometriosis, malignant transformation, molecular basis, management

DR. CHUA PENG TENG

CONSULTANT OBSTETRICIAN & GYNAECOLOGIST, ADVANCED MIS SURGEON, MAHKOTA MEDICAL CENTRE

Dr Chua graduated from Manipal, India with an MBBS degree and subsequently went on to obtain his Masters in O&G from the Conjoint Board of O&G, IIUM, Malaysia. He has been in active practice in various hospitals in Malaysia and owing to his passion in Gynaecologic Minimally Invasive Surgery, he obtained Fellowship & Diploma in Minimal Access Surgery in New Delhi, India. During his stint in India, he received the Merit Certificate for Gynaecologic Laparoscopist. After completing his fellowship in MAS, He subsequently trained under Professors Chyi-Long Lee & Kuan-Gen Huang, in Linkou Chang Gung Memorial Hospital, focusing in Advanced & Gynae-Oncologic Minimally Invasive Surgery.

He was admitted as a Fellow of the American College of Surgeons in 2018 and being active in academia he is also a member of the Academy of Medicine, College of O&G, Malaysia. Dr Chua's other engagements include being a member of the American Association of Gynaecologic Laparoscopists (AAGL) and he was previously serving in the committee for the Gynaecologic Endoscopic Society of Malaysia(GESM). Dr Chua's areas of practice include VNOTES/ Single Port surgery, Gynae-Oncologic Minimally Invasive Surgery; in particular Sentinel Lymph Node techniques as well as Laparoscopic Radical Hysterectomies for Gynaecologic Cancers. He serves in the APAGE-MIT teaching faculty for Single Port/VNOTES procedures. He is also a journal reviewer for Gynaecology & Minimally Invasive Therapy (GMIT), a peer-reviewed journal for the Asia Pacific region. Dr Chua has published papers on various topics, in particular Cervical Cancer with best paper award from the Taiwan Association for Minimally Invasive Gynaecology (TAMIG). He is currently a member in the Gynaecologic Endoscopy Sub-Committee of the Obstetrical & Gynaecological Society Of Malaysia (OGSM).

LAPAROSCOPIC MANAGEMENT OF ENDOMETRIOSIS & OVARIAN ENDOMETRIOMA

Endometriosis poses significant challenge during surgery owing to the distortion of anatomy as well as difficulties in establishing clear planes for dissection. This is more so during laparoscopic surgery where the tactile feedback is limited.

Ovarian Endometrioma is a commonly found among patients suffering from endometriosis and the clinical presentations do not always correlate with underlying severity of the disease.

In this lecture, various surgical techniques and approaches on how to deal with the endometriosis spectrum during laparoscopic surgery will be elucidated as well as presenting a focused view on ovarian endometrioma and it's dilemmas in Gynaecologic practice.

DR. YEN, CHIH-FENG

VICE CHAIR OF THE DEPARTMENT OF OBSTETRICS & GYNAECOLOGY, LINKOU CHUNG GUNG MEMORIAL HOSPITAL, TAIWAN

Chih-Feng Yen, MD, PhD, graduated from Taipei Medical University (MD) and Graduate Institute of Clinical Medical Sciences of Chang Gung University (PhD), is the vice Chair of the Department of Obstetrics and Gynecology, Linkou Chang Gung Memorial Hospital (CGMH), and Associate Professor of Chang Gung University, Taiwan. He was the past President of Taiwan Association for Minimally Invasive Gynecology (TAMIG, 2013-2014). Currently he serves as the Secretary General of the Asia-Pacific Association for Gynecologic Endoscopy and Minimally Invasive Therapy (APAGE), and the Standing board of Supervision of the Taiwan Endometriosis Society (TES).

A/Prof. Yen provides clinical expertise in gynecologic endoscopy with successful experiences for thousands of patients with laparoscopic and/or hysteroscopic operations. He also focuses on the current advanced laparoscopic techniques, including laparoendoscopic single-site (LESS) surgery, natural orifice transluminal endoscopic surgery (NOTES), and robot-assisted laparoscopic surgery recently. His research program focused on adenomyosis, endometriosis, and the molecular and cellular biology of endometrium.

A/Prof. Yen was a visiting assistant professor at Yale University School of Medicine, and authored over 100 peerreviewed papers, primarily in the field of gynecologic endoscopy and reproductive sciences, and has written several textbook chapters. He is currently the Editorial Board member of the Journal of Minimally Invasive Gynecology (JMIG), which is the official Journal of AAGL; and the Managing Editor of Gynecology and Minimally Invasive Therapy (GMIT), the official journal of APAGE; as well as the reviewer of several internationally renowned journals.

DIAGNOSIS & LAPAROSCOPIC MANAGEMENT OF DEEPLY INFILTRATING ENDOMETRIOSIS

Deep endometriosis (DE), previously known as deep infiltrating endometriosis (DIE), is defined as endometriosis involving the bowel, bladder, ureter, vagina, parametrium (cardinal ligament), diaphragm, and other pelvic floor structure if the muscularis layer is affected. Lesions usually can be noted with dense adhesions and/or endometriotic infiltration up to >5 mm in depth. The colorectal involvement by deep endometriotic nodules represents almost 90% of these cases, and intestinal involvement has been estimated in 8–12%. Multifocality is one of the main characteristics of DE. The high incidence of surgical morbidity involved with bowel is challenging and poses a therapeutic dilemma for the surgeon.

In several patients, the presence of deep endometriosis coincides with other forms of endometriosis. Compared with ovarian endometriosis, DE is associated more frequently with dyspareunia, noncyclic pelvic pain, as well as specific bowel symptoms, including cyclic bowel alterations, dyschezia and rectal bleeding. The relationship between DE and infertility is controversial.

Pre-operative planning is fundamental for defining the optimal therapeutic strategy; individual and clinical factors, pre-operative morphologic characteristics from imaging, surgical considerations and impact on quality of life are critical variables that should be considered. Patient counseling are fundamental for defining the optimal therapeutic strategy, especially the potential risks of surgical treatment.

Asymptomatic patients whose lesions were diagnosed on clinical exam and/or radiologic findings do not systematically warrant surgery. However, a large lesion that compromises the lumen of the recto-sigmoid, a severe hemorrhage, or a progressive disease, can be an indication for surgery.

When surgery is indicated, involvement of a multidisciplinary surgical team is required. Surgeons must have a significant knowledge of pelvic anatomy to have an approach to a grossly distorted surgical field. Thus, pelvic anatomical landmarks represent essential points of reference to start procedures such as mobilization of the pelvic viscera, wide peritoneal resections or the identification of further anatomical structures to be preserved, such as bowel, ureter, vessels and parasympathetic and orthosympathetic pelvic neural fibers in nerve-sparing procedures. A bowel surgeon, a urologist, a thoracic surgeon and even a plastic surgeon may need to be involved.

Recent review showed excellent results of surgical treatment, with >85% women showing complete improvement of symptoms and recurrence rates lower than 5%. However, surgery is not always successful and can be partially attributed to disease heterogeneity in complexity, surgical experience, and anatomical locations of the disease.

Reference:

1. Abrao, M. S., et al. (2015), Hum Reprod Update, 21 (3), 329-39.
2. Working group of ESGE, ESHRE, et al. (2020), Hum Reprod Open, 2020 (1), hoaa002.

ADENOMYOSIS & LAPAROSCOPIC ADENOMYOMECTOMY

Adenomyosis is a complex disease that manifests in a multitude of ways. It usually presented symptoms of hypermenorrhea (60%), dysmenorrhea (25%), compression, subfertility, chronic pelvic pain, etc. Typically, the adenomyotic lesions arise from the inner layer of myometrium, which suggest the pathogenesis of endometrial invagination or metaplasia from the endometrial-myometrial interface. However, the lesions could also be noted focusing on the outer layer of myometrium, which suggests the implantation of regurgitated endometrial tissue. Different mechanisms of pathogenesis suggest that adenomyosis is a heterogenous disease. Hysterectomy is a highly effective and recommended treatment option for symptomatic adenomyosis.

Approximately 20% of involve women <40 years old who usually hopes uteruspreserving options. Laparoscopic adenomyomectomy, thought feasible, is technically challenging because of the continuity of the adenomyotic lesion with the healthy myomectomy and endometrium without a clear margin. Therefore, the procedures should be delicately planned to maximize the excision of adenomyotic lesion as well as to retain the adequacy of myometrium for repair, as to maintain the uterine wall integrity after reconstruction for those who plans for further conception. The myometrium should at least be 9-15 mm in thickness to avoid uterine rupture in subsequent pregnancy.

The symptomatic relief of uterus-preserving surgery was reported satisfactory in most patients, and the fertility benefits was suggested only in women ≤39 years in studies. However, paucity of good quality evidence was noted in current literature and further well-designed prospective comparative studies were awaited.

DR. SEVELLARAJA SUPERMANIAM

REPRODUCTIVE MEDICINE SPECIALIST, ADVANCED MIS SURGEON, MAHKOTA MEDICAL CENTRE

Dr. S. Selva is a Consultant Obstetrician and Gynaecologist and a subspecialist in Reproductive Medicine at the Mahkota Medical Centre in Melaka, Malaysia. He also heads the IVF Centre at this hospital.

He is a Fellow of the Royal College of Obstetrician and Gynaecologist. He obtained his Masters in Reproductive Medicine from the University of Western Sydney in 2003.

He is the Past President of the Obstetrical and Gynaecological Society of Malaysia He is a Past President of the Asia Pacific Association Of Gynaecological Endoscopy (APAGE) , board member of APGET (Asia Pacific Gynaecological Endoscopy Group). He is also a Past board member of the International Society of Gynaecological Endoscopy and a reviewer of the journal of the Asia Pacific Association of Gynaecological Endoscopy (APAGE).

Dr. Selva is a dedicated laparoscopic surgeon and has performed about 8000 cases so far. He also runs a Fellowship in Minimally Invasive Surgery and Infertility at Mahkota Medical Centre the first of its kind in a private hospital in Malaysia. So far he has trained 9 gynaecologists.

He published his first book entitled “Laparoscopic Surgery in Gynaecology and Common Diseases in Women” a book to educate the public and doctors on the benefits of Laparoscopic Surgery in Women. He has also numerous publications in international journals mostly on the topic of minimally invasive surgery and fertility. He also runs a blog and a podcast entitled “ Surviving Private Practice in Malaysia”.

He just started the first “Ultrasound based HIFU centre” at Mahkota Medical Centre, Melaka and will be providing non invasive surgery for fibroids and adenomyosis

HIFU - A NEW HOPE IN THE MANAGEMENT OF ADENOMYOSIS

Adenomyosis is a difficult disease to treat. There are 2 groups of patients who we see with adenomyosis. The first group are those who have completed their families and want only relief of their symptoms namely heavy menses and dysmenorrhoea. The second group are patients with adenomyosis who want to conceive. Current treatment options are more for patients who do not want to conceive. These options are: continuous oral contraceptives, dienogest, depoprovera injection, Mirena and hysterectomy. As for patients who want to conceive the only available option is adenomyomectomy. We all know that adenomyomectomy is not an easy operation and is reserved for patients with adenomyoma. In patients with globular adenomyosis, adenomyosis interna and ademyosis externa involving the entire posterior or anterior wall, it is difficult to perform an adenomyomectomy. High Intensity Focused Ultrasound (HIFU) provides a non invasive option for these patients. In patients who have completed their families with adenomyosis and not responding to medical treatment and not keen on hysterectomy, HIFU can be done to ablate as much of the adenomyosis as possible. In these patients we can be aggressive in the ablation and even the endometrium can be ablated to reduce menses thus relieving heavy menses and dysmenorrhoea. In patients who are keen to conceive HIFU can be used to ablate the adenomyosis but here we are more careful to preserve the endometrium for future pregnancy. Symptoms can be relieved and shrinkage of the adenomyosis will occur thus improving pregnancy rates. Here I will show 2 cases of adenomyosis which we ablated recently showing the extent of the ablation.

Case 1 is a 23 year old single lady with severe painful menses. Figure 1 shows that she has a large posterior adenomyosis interna. Figure 2 shows the contrast MRI of the same patient. In this patient HIFU need to be done carefully so as to preserve the endometrial cavity. Her HIFU sonification time was 800 s. Figure 3 is contrast MRI done one day after HIFU. It shows the ablated areas of adenomyosis which appears as darker areas on the contrast MRI.

Case 2 a 47 year old single lady with heavy and painful menses. She is not keen on pregnancy. Figure 4 shows the MRI of the pelvis showing a large posterior adenomyosis interna with 2 small anterior subserous fibroids. Fig 5 shows contrast MRI before HIFU treatment. Since this patient is not keen on pregnancy, we could do extensive ablation of the adenomyosis. The endometrium was also ablated. Sonication time was1632 s. Figure 6 shows the contrast MRI done one day after the HIFU. Note the large area of ablation and even the endometrium has been ablated. This will give good relief of her symptoms and so she need not have to undergo a hysterectomy

Endometriosis KILLS QUALITY OF LIFE

What is Endometriosis?

Endometriosis is a disease that crippled the pelvis caused by the presence of endometrium at places outside the womb in the pelvis which leads to a chronic inflammation and damage to the entire reproductive system. It severely affects women's fertility potential and compromises quality of life.

What is the burden of Endometriosis?

Almost 10% of women worldwide have endometriosis. In Malaysia, it is estimated about 1 in 10 women suffers from endometriosis. However, the prevalence among the women with infertility is reported as high as 30% - 50%. About 20% of women with chronic pelvic pain suffer from endometriosis.

Endometriosis disease may begin as early as in young teenager as severe period pain but the diagnosis and treatment are commonly delayed to adulthood when they presented with more severe disease.

Over 60% of women affected by endometriosis have increased risk multiple surgeries due to recurrent disease and a higher chance of developing ovarian cancer in comparison with the general population.

Symptoms and signs of Endometriosis

- Pain before and during periods
- Pain during sex
- Infertility
- Unusual fatigue or tiredness
- Painful urination during periods
- Painful bowel movements during periods
- Gastrointestinal upsets such as diarrhea or constipation
- Raised tumour maker Ca125

Clinical Manifestation and Stages of Endometriosis

Similarly, like cancer, endometriosis may manifest in many stages and severity which often does not correlate with the symptom of the patient. There are patients who have severe painful periods but less severe stage 1 or 2 disease. But there are a number of patients who has no symptom at all or very minimal pain but has severe stage 3 or 4 disease. The severer the disease the more crippled the pelvis gets. As a consequence, it might lead to long term complication like infertility, poor quality of life, involvement of other interna organs and malignancy.

Below are the manifestation and type of endometriosis.

- Endometriotic or chocolate ovarian cyst
- Superficial endometriosis
- Deeply infiltrating endometriosis
- Adenomyosis

Medical treatment of Endometriosis

For younger women, those who are not desiring pregnancy, and has less severe disease, medical and hormonal therapy have been proven effective to control pain symptom, regulate periods and to control the progression of the disease to a more severe stage. Among the options of medical treatment that are often prescribed by the doctor are NSAIDS drugs, oral contraceptive pills, progestins and gonadotrophin analogues. However, poor compliance and intolerable side effect to medical therapy often pose a challenge to treat the disease effectively for long term disease control.

Who Needs Surgery in Endometriosis?

The following are the indications or reasons where surgery is necessary to effectively treat endometriosis:

- Failed medical therapy
- Infertility
- Endometriotic or chocolate cyst of the ovary
- Deeply infiltrating endometriosis
- Suspected malignancy
- Bowel or bladder endometriosis

Laparoscopic or Key-Hole Surgery for Endometriosis and Its Advantages

The aim of surgery in endometriosis is to excise the disease and restore the pelvic anatomy and its function. Compared to open conventional surgery, laparoscopic surgery i.e. operating through a few small holes has been proven beneficial and advantageous to women who is undergoing a surgery for a benign gynaecological condition like endometriosis. The following are advantages laparoscopic surgery in endometriosis

- Less painful
- Less use of painkillers
- Small and invisible scars
- Faster recovery
- Faster discharge from hospital
- Faster return to work
- Less adhesion complication
- Better detection and clearance of disease lesion
- Better evaluation and staging especially in deep endometriosis

With the advanced medical technology and sophisticated endoscopic devices, minimally invasive surgery has been not only made possible in most of gynecological diseases but also safe and beneficial to women. If operation is required, discuss with your doctor and opt for a way forward i.e. laparoscopic surgery.

Written by:

Dr Sharifah Halimah Jaafar
MD (UKM) M.Med O&G (UKM)
AM (Mal) AAAM (USA)
Consultant Obstetrician & Gynaecologist
Minimally Invasive Surgeon in Gynaecology
Regency Specialist Hospital, Johor, Malaysia

GlobalHealth AWARDS 2020
OBSTETRICIAN & GYNAECOLOGIST
CLINIC OF THE YEAR IN ASIA PACIFIC



WHAT IS Gynae-Oncology ALL ABOUT?

At the first glance it doesn't ring many bells in the medical fraternity, more so to the larger public. Essentially, women health deals with pregnancy, gynaecological issues from adolescent stage to menopausal period. The range of disease varies from non malignant or hormonal conditions to cancerous ones. Gynae-oncology relates to precancerous and cancer conditions of the female reproductive organs, i.e the uterus, cervix, tubes, ovaries, vagina and the vulva. The range of treatment varies from complex gynaecological surgeries, chemotherapy, radiotherapy and palliative care issues.

How likely is a woman to get cancer from her reproductive organs?

Depending on the age and site of organs ,the answer varies. For example, 85% of cancer ovary are multifactorial and age related, and only 10 - 15% are genetically linked and hereditary, possibly passed down through the family tree. Should one be affected with this defective gene, the lifetime risk can go up to as high as 30 - 45% of having cancer ovary. We also do know, however that smoking is significantly related to cancer diseases.

Can women be screened for female cancers?

Yes and no. There have been established modalities and methods for screening of cervical cancer, but the same cannot be said for non genetically linked ovarian or uterine cancer. However, general health awareness and healthy lifestyle practices are already part of the battle for minimizing the risk of cancer diseases.

I'm too young to get cancer...

In the present context and modern world, due to the improvement in screening modalities, better society awareness, change of lifestyle habits and environmental carcinogenic exposures and longer life expectancy, the number of cancer occurrence and deaths have been on the steady increase. This is irrespective of the age and gender when diagnosed. Also, certain genetic conditions makes one more predisposed towards gynaecological cancers, especially cancer ovary.

Is it true certain diet fads / taking supplements can reduce risk of cancer?

The present available medical evidence at a global scale do not support such popular beliefs and claims, as purported by the social media and individual testimonial efforts. It's best to understand the basic tumor behaviour and the physiology involved, before staking claim over such facts. Always consult the appropriate doctor / person in charge before embarking on any kind such gastronomic adventure as there have been reported cases of liver and kidney failure directly related the consumption of these products.

Should I get HPV vaccination? I've heard many scary rumors about it...

HPV stands for Human Papilloma Virus, which is largely responsible for precancer and cancer conditions of cervix. HPV vaccine, has been approved globally and widely accepted in more than 84 countries, largely incorporated into their national vaccination programme for young boys and girls (11-14 yrs of age). More recent advances have seen the vaccine (Gardasil 9) approved for vaccinations of adult male and female between ages 24 to 45 yrs age (FDA, USA). Countries which have adopted this vaccination on a large scale, like Australia, have seen a significant drop in the percentage of precancer conditions of the cervix, anus and genital warts compared to prevaccination era. International datas in various continents and across South East Asia countries have shown very good safety profile and minimal vaccine complications.

Who should I see if I think I need further help and explaination?

Ideally, please consult a trained gynaeoncologist to get the appropriate information and councelling. Alternatively, you may consult your family doctor or gynaecologist who may then discuss or refer you to someone who is suitable and qualified.

Written by:
Dr Badrul Zaman Bin Muda @ Abdullah
MBBS, FRCOG
Consultant of Gynaeoncologist
Regency Specialist Hospital, Johor, Malaysia

Adenomyosis AFTER HIFU

Adenomyosis is a difficult disease to treat. Most patients with adenomyosis will present with heavy and painful menses and infertility. There is no good treatment for adenomyosis especially for women who want to conceive. Here I will highlight 2 cases where HIFU can be used to treat adenomyosis.

Case 1 is a 23 year old single lady with severe painful menses. Figure 1 shows that she has a large posterior adenomyosis. Figure 2 shows the contrast MRI of the same patient. In this patient HIFU need to be done carefully so as to preserve the endometrial cavity. Her HIFU sonification time was 800 s. Figure 3 is contrast MRI done one day after HIFU. It shows the ablated areas of adenomyosis which appears as darker areas on the contrast MRI.

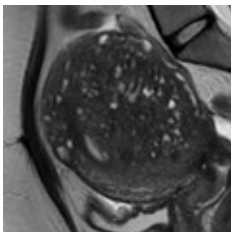

Figure 1

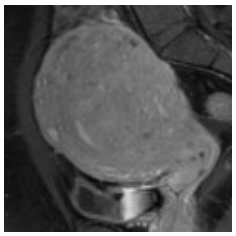

Figure 2

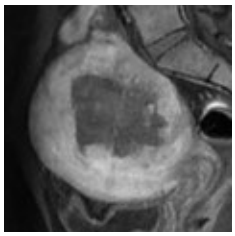

Figure 3

Case 2 a 47 year old single lady with heavy and painful menses. She is not keen on pregnancy. Figure 4 shows the MRI of the pelvis showing a large adenomyosis with 2 small anterior subserous fibroids. Fig 5 shows contrast MRI before HIFU treatment. Since this patient is not keen on pregnancy, we could do extensive ablation of the adenomyosis. The endometrium was also ablated. Sonication time was1632 s. Figure 6 shows the contrast MRI done one day after the HIFU. Note the large area of ablation and even the endometrium has been ablated. This will give good relief of her symptoms and so she need not have to undergo a hysterectomy.

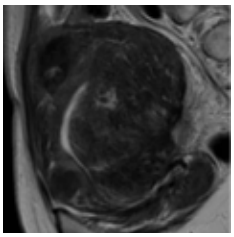

Figure 4

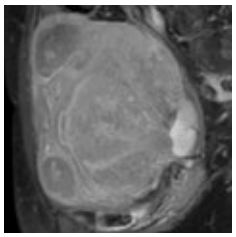

Figure 5

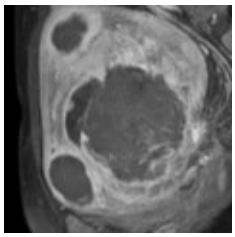

Figure 6

Written by:

Dr. Sevellaraja Supermaniam

MBBS (MAL) FRCOG (UK), FICS Masters in Reproductive Medicine (Sydney), Bachelor in Laparoscopy (Belgium)
Reproductive Medicine Specialist, Advanced MIS Surgeon,
Mahkota Medical Centre

WHAT ARE Endometriosis & Endometrioma?

Endometriosis happens when tissue that is normally found inside the lining of the womb(uterus) grows outside its normal location. Endometriosis can affect many organs, be it in the local vicinity (ovaries, external uterine wall, abdominal wall, fallopian tubes, bladder, bowel and even diaphragm, upper abdomen and thoracic regions). There were case reports of central nervous system affliction as well. Other less common sies include surgical wound endometriosis, causing the patient to bleed from such wounds, related to her menstrual cycles.

When the tissue grows on an Ovary(female gonad) it gives rise to cyst-like structure called "Endometrioma". This cyst usually contains chocolate/dark coloured fluid or blood hence often referred to as "chocolate cyst".

The exact cause of endometriosis remains unknown. The most accepted theory is the retrograde menstruation theory by Sampson. During menstruation, parts of the inner lining of the uterus move towards the abdominal cavity through the fallopian tubes and stick to various organs of the abdomen,pelvis or to the ovaries. These "endometrial implants" become "endometriotic lesions". The hormone oestrogen maybe crucial in this process as it is one of the key hormones controlling the menstrual cycle, researches have however remain in debate as there is still no direct causative link. Genetic, environmental and immune factors may also play an important role in the development of endometrioma.

Investigations are tailored based on patient symptoms and the stage of the disease. In patients with infertility, further investigations may be required to evaluate the extent of the disease especially if it affects the fallopian tubes. Serum Anti-Mullerian Hormone can be done to check the ovarian reserve prior to surgery and if warranted, egg or embryo preservation can be offered to patient before laparoscopic surgery. For patients with significant pain, attention would be to remove disease based on anatomical regions involved. In endometrioma, one of the major concerns is to differentiate endometriosis from a malignant condition since endometriosis patients have an average 4 times increased risk of ovarian cancer. In such cases, imaging and tumour marker levels may not reflect the true extent of underlying disease and very often clinical judgement can only be made intraoperatively especially with the help of Frozen Section Histopathology.

Long-term prognosis depends on the extent of the disease and size of the endometrioma. Recurrence is common, and life-long follow up is warranted. This is more so when most patients present in their early reproductive years at the age of less than 40. Treatment strategies will be to relieve pain by medical or surgical means and most importantly to improve the patient's quality of life as this debilitating disease often causes relationship distress and disrupts activities of daily living for the patient.

Endometriosis can affect multiple organs. In this picture, the appendix is affected by multiple endometriotic spots

Endometrioma commonly contains "chocolate" fluid material, hence also called as Chocolate Cysts

Written by:
Dr Chua Peng Teng
MOG, FACS
Consultant Obstetrician & Gynaecologist, Advanced MIS Surgeon
Mahkota Medical Centre

Case Report

Beng Kwang Ng[1] / Su Ee Phon[2] / Ani Amelia Zainuddin[2] / Wendy Yin Ling Ng[3] / Nordashima Abd Shukor[4] / Pei Shan Lim[2]

Bowel endometriosis: a diagnostic and therapeutic challenge

[1] Department of Obstetrics and Gynaecology, UKM Medical Centre, Jalan Yaacob Latiff, Cheras, 56000 Kuala Lumpur, Malaysia, Phone: +603-91455949, Fax: +603-91456672, E-mail: nbk9955@ppukm.ukm.edu.my
[2] Department of Obstetrics and Gynaecology, UKM Medical Centre, Kuala Lumpur, Malaysia
[3] Department of Radiology, Hospital Kuala Lumpur, Kuala Lumpur, Malaysia
[4] Department of Pathology, UKM Medical Centre, Kuala Lumpur, Malaysia

Abstract:
Bowel endometriosis is the most common extragenital manifestation of endometriosis. Clinical suspicion is of utmost importance for achieving its diagnosis. Management of this condition is, however, always challenging to the gynaecologist. We report a case of bowel endometriosis in which the patient presented with dyschezia and haematochezia prior to her menses for the past 2 years. A 44-year-old para two woman presented with worsening dysmenorrhea and dyspareunia. She also experienced dyschezia and haematochezia prior to her menses for the past 2 years. An examination revealed a fixed retroverted uterus. A computed tomography scan showed focal bowel thickening. She underwent a colonoscopy examination and biopsy that revealed stromal endometriosis. She was subsequently treated with dienogest and became asymptomatic. Diagnosis and management of this debilitating illness was revisited and discussed.

Keywords: bowel, dienogest, endometriosis, extragenital, progesterone
DOI: 10.1515/hmbci-2017-0051
Received: July 10, 2017; **Accepted:** July 28, 2017

Case report

Endometriosis is a chronic gynaecological condition, which is characterised by ectopic location of endometrial stroma and glands. It affects 6%–10% of women of reproductive age and up to 55% of infertile patients who underwent laparoscopic evaluation for subfertility [1], [2]. Phenotypically, three types of endometriosis are distinguished: ovarian endometrioma, superficial peritoneal endometriosis and deep infiltrating endometriosis (DIE). DIE is the most severe form, which may involve the rectovaginal region, as well as the bowel, ureters and bladder [3], [4]. Among all extragenital endometrioses, bowel endometriosis predominates with a prevalence of 3%–12%, mostly affecting the rectosigmoid junction (50%–90%), followed by the small bowel (2%–16%), appendix (3%–18%), caecum (2%–5%) and ileum (4%) [5], [6]. We report a case of bowel endometriosis which responded well to medical therapy without the need for surgery.

A 44-year-old para two woman presented with worsening dysmenorrhea and deep dyspareunia for a duration of 1-year. She also experienced dyschezia and haematochezia 2 days prior to every menstruation. She sought treatment from a private gynaecologist and was referred to us for suspected bowel endometriosis. She had two pregnancies between 1998 and 2000. She had used a copper intrauterine device till the year 2006 and subsequently the couple practised the male barrier method. She was the fifth child out of six. There was no similar family problem that suggested any hormonal dysfunction among her siblings.

On assessment, she was pale with a blood pressure of 126/80 mm Hg and a pulse rate of 94 beats per minute. She stood at a height of 156 cm and weighed 56 kg. Her body mass index was 23.2 kg/m^2. Her abdomen was soft and non-tender. The uterus was just palpable. Bimanual examination revealed a 12-week-sized uterus with restricted mobility and a fixed mass at the pouch of Douglas, with thickened bilateral uterosacral ligaments. Rectal examination showed a lobulated and boggy mass, anterior to the rectum, 6 cm proximal to the anal verge.

Her haemoglobin level was 7.7 g/dL and she was transfused with two units of blood. Her serum cancer antigen 125 (CA 125) was elevated to 77 U/mL. A pelvic ultrasound showed an anteverted uterus with an anterior intramural fibroid measuring 4.5 × 4.9 cm and another smaller posterior wall fibroid measuring 2.0 × 1.5

Beng Kwang Ng is the corresponding author.

cm. Both her ovaries were normal. Her computed tomography (CT) scan showed focal bowel wall thickening involving the sigmoid colon with luminal narrowing (Figure 1). On colonoscopy, the rectal mucosa was inflamed and indurated. There was external compression of the rectum measuring 10–15 cm from the anal verge at its anterior aspect. A biopsy taken at the bowel wall was consistent with stromal endometriosis. Microscopically, the fragments of colonic mucosa showed multiple micronodules of benign endometrial stroma without glandular component within the lamina propria, which was associated with haemorrhage (Figure 2). There were no malignant cytological features. Immunohistochemical study revealed CD10 and oestrogen receptor (ER) expression in the endometrial stroma. Hormonal assays such as serum progesterone, prolactin, follicle-stimulating hormone and luteinizing hormone were not taken in this patient.

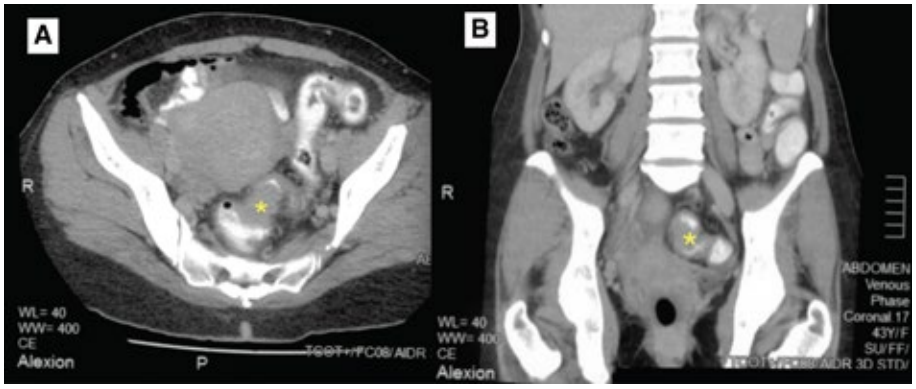

Figure 1: Axial (A) and coronal (B) CT images showed a lobulated soft tissue density mass (*) causing narrowing at the proximal sigmoid colon.

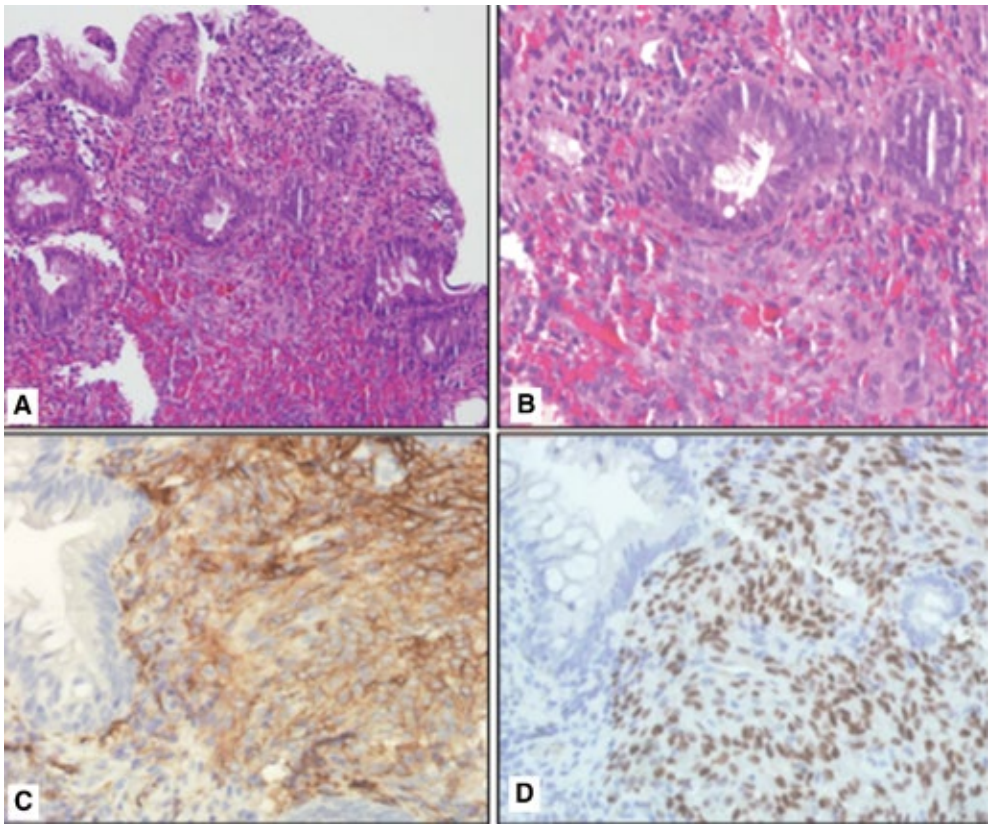

Figure 2: (A) and (B). A fragment of rectal mucosa harbouring a few micronodules of benign endometrial stroma within the lamina propria. There are no endometrial glands present (H&E 200×, 400× mag.) (C) Strong cytoplasmic positivity of endometrial stromal cells for CD10 (CD10 400× mag.) (D) The endometrial cells show nuclear positivity for oestrogen receptor (ER 400× mag.).

Both medical therapy and surgical management were explained and medical treatment was opted. Her symptoms resolved at 3 months of Visanne® (Dienogest) treatment. She is currently on the same treatment after 6 months of follow up.

López Carrasco et al. [6] reported that among 150 patients operated for symptomatic DIE nearly 50% of the patients had bowel endometriosis. Clinical manifestations of bowel endometriosis tend to be nonspecific, and often mimic other pathologies, making diagnosis extremely challenging. The estimated delay in diagnosis is from 3 to 9 years and the number is greater in patients who present with infertility rather than bowel symptoms [3].

Apart from the usual symptoms of endometriosis, i.e. cyclical pelvic pain, dysmenorrhea and dyspareunia, patients may present with bowel-specific symptoms, i.e. dyschezia and haematochezia, as in this case. Rare presentation of bowel endometriosis includes acute bowel obstruction, necessitating emergency surgery [7]. Physical examination is the first step in the evaluation of patients suspected to have endometriosis. However, findings are highly variable depending on the size and location of the ectopic tissue as well as clinical experience of the person who performs the examination. Findings suggestive of bowel endometriosis include palpable nodules at the rectosigmoid space. Clinical history and physical examination are often inadequate, hence biochemical markers and imaging modalities are often engaged to assist in the diagnosis of bowel endometriosis.

Although CA125 is not a specific marker for intestinal endometriosis, studies have found that this marker is often significantly increased in women with severe form of endometriosis, especially in the case of DIE [8]. Transvaginal ultrasound (TVS) has long been used as the first line imaging modality to diagnose endometriomas. Recent studies have proved its role in the evaluation of DIE. With the use of TVS after bowel preparation, bowel endometriosis appears as an irregular hypoechoic mass penetrating into the muscularis propria layer of the bowel wall. On colour flow Doppler, the mass demonstrates low vascularity. On the other hand, transrectal ultrasound is good for detecting endometriotic lesions at the rectovaginal region [3].

Magnetic resonance imaging (MRI) is the imaging modality of choice in evaluating DIE, particularly if the infiltrating implants are situated at the posterior compartment, such as the uterosacral ligaments, rectovaginal septum, vagina and rectum. On the contrary, in bowel endometriosis, it lacks the ability to provide adequate information regarding the extent of intestinal wall involvement. In this context, modified virtual colonoscopy, also known as CT colonography (CTC), is a more reliable diagnostic tool for determining bowel infiltration. It provides multilane reconstruction and anatomical correlation between a specific lesion and a selected landmark. In addition, the resulting images are less confounded by bowel peristalsis and faecal matter. Thus, CTC has a higher diagnostic accuracy as compared to MRI [9]. Baggio et al. [10] showed that CTC has the highest accuracy in detecting bowel endometriosis as compared to clinical evaluation, serum CA 125 and TVS.

Treatment of bowel endometriosis includes both conservative and surgical management. Similar to other forms of endometriosis, medical therapy, such as non-steroidal anti-inflammatory drugs, combined hormonal contraceptives and progestogens, should always be considered as the first-line therapy, as they are effective, safe and well tolerated with minimal side effects [11]. Gonadotropin-releasing hormone agonists (GnRHa) significantly reduce dysmenorhoea and pelvic tenderness; however, they are associated with higher rates of adverse effect such as sleep disturbances [12].

Dienogest (Visanne®) is a synthetic progesterone with unique properties that has gained popularity since the past few decades. It has been shown to reduce pelvic pain associated with endometriosis. Its efficacy was comparable to GnRHa in improving the combined symptoms and signs score as well as the revised American Fertility Society staging scores [13], [14]. Dienogest was well tolerated with fewer hypoestrogenic effects than GnRHa but it was associated with a higher incidence of abnormal menstrual bleeding [13]. This patient also experienced an irregular menstrual bleeding pattern while on Dienogest; however, it was well tolerated. There was no further drop in the haemoglobin level and she remained asymptomatic.

Recent data have proved that both surgical excision and medical treatment are equally effective in improving pain symptoms associated with deep endometriosis [15]. Therefore, surgical excision of DIE should only be considered in patients who failed medical treatments, or in the presence of sub-occlusive symptoms suggestive of bowel stenosis [4]. However, the benefits of surgery in terms of improvement in pain and quality of life (QOL) should always be weighed against the possible serious complications such as rectovaginal fistula and anastomotic leakage [4].

In conclusion, symptomatic deep endometriosis i.e. bowel involvement remained challenging in terms of diagnosis and its subsequent management. Medical therapy should be offered as the first-line option before planning for definitive surgery by an experienced surgeon. This is important to minimise potential serious complications while maintaining excellent QOL for the affected women.

Author Statement

Research funding: Authors state no funding involved.

Conflict of interest: Authors state no conflict of interest.

Informed consent: Informed consent has been obtained from all individuals.

Ethical approval: The research related to human use complies with all the relevant national regulations and institutional policies and was performed in accordance the tenets of the Helsinki Declaration.

References

[1] Giudice LC. Clinical practice. Endometriosis. N Engl J Med. 2010;362:2389–98.
[2] Mishra VV, Bandwal P, Agarwal R, Aggarwal R. Prevalence, clinical and laparoscopic features of endometriosis among infertile women. J Obstet Gynaecol India. 2017;67:208–12.
[3] Darvishzadeh A, Mcachern W, Lee TK, Bhosale P, Shirkhoda A, Menias C, et al. Deep pelvic endometriosis: a radiologist's guide to key imaging features with clinical and histopathological review. Abdom Radiol (NY). 2016;41:2380–400.
[4] Berlanda N, Somigliana E, Frattaruolo MP, Buggio L, Dridi D, Vercellini P. Surgery versus hormonal therapy for deep endometriosis: is it a choice to the physician?. Eur J Obstet Gynecol Reprod Biol. 2017;209:67–71.
[5] Chapron C, Chopin N, Borghese B, Foulot H, Dousset B, Vacher-Lavenu MC, et al. Deeply infiltrating endometriosis: pathogenetic implications of the anatomical distribution. Hum Reprod. 2006;21:1839–45.
[6] López Carrasco A, Hernández Gutiérrez A, Hidalgo Gutiérre PA, Rodríguez González R, Marijuán Martin JL, Zapardiel L, et al. Ileocecal endometriosis: diagnosis and management. Taiwan J Obstet Gynecol. 2017;56:243–46.
[7] Bidarmaghz B, Shekhar A, Hendahewa R. Sigmoid endometriosis in a post-menopausal women leading to acute large bowel obstruction: a case report. Int J Surg Case Rep. 2016;28:65–7.
[8] Santulli P, Streuli I, Melonio I, Marcellin L, M'Baye M, Bititi A, et al. Increased serum cancer antigen-125 is a marker for severity of deep endometriosis. J Minim Invasive Gynecol. 2015;22:275–84.
[9] Jeong SY, Chung DJ, Myung Yeo D, Lim YT, Hahn ST, Lee JM. The usefulness of computed tomographic colonography for evaluation of deep infiltrating endometriosis: comparison with magnetic resonance imaging. J Comput Assist Tomogr. 2013;37:809–14.
[10] Baggio S, Zecchin A, Pomini P, Zanconato G, Genne M, Motton M, et al. The role of computed tomography colonography in detecting bowel involvement in women with deep infiltrating endometriosis: comparison with clinical history, serum Ca 125 and transvaginal sonography. J Comput Assist Tomogr. 2016;40:886–91.
[11] Rafique S, Decherney AH. Medical management of endometriosis. Clin Obstet Gynecol. 2017;60:485–96.
[12] Brown J, Farquhar C. An overview of treatments for endometriosis. J Am Med Assoc. 2015;313:296–7.
[13] McComack PL. Dienogest: a review of its use in the treatment of endometriosis. Drugs. 2010;70:2073–88.
[14] Andres M, Lopes LA, Baracat EC, Podgaec S. Dienogest in the treatment of endometriosis: systematic review. Arch Gynecol Obstet. 2015;292:523–9.
[15] Kössi J, Setälä M, Mäkinen J, Härkki P, Luostarinen M. Quality of life and sexual function 1 year after laparoscopic rectosigmoid resection for endometriosis. Colorectal Dis. 2013;15:102–108.

Written by:
ASSOCIATE PROF
DR. ANI AMELIA BT DATO ZAINUDDIN
CONSULTANT IN PAEDIATRIC & ADOLESCENT GYNAECOLOGY,
DEPT OBSTETRICS & GYNAECOLOGY,
HOSPITAL CANSELOR TUANKU MUHRIZ (HCTM) UKM

Natural history of ovarian endometrioma in pregnancy

Katie Pateman, Francesca Moro, Dimitrios Mawelos, Xulin Fœ, Wee-Liak Hoo and Davor Jurkovic"

Abstract

Background: Ovarian endoowtriomas are classified as benign ovarian lesions. During p'egnaricy endorfwtriomas may undergo major morphological changes which are referred to a 'decidualisation'. Decidualised ovarian endor mrioma may resemble mdignani ovaian tumours on ultrasound examination The aim was la study v6fiations in the mophology and size of ovarian endometriornas diagnosed on ultrasound during pregnancy.

Methods: We searched oui database to identify pregnant women who were diagnosed with ovarian endometriomas on ulvasound ‹n order to study rhe effect of pregnancy.on their morphological characteristics In worn°n who urdervvent señal scans during pregnancy we examined the changes in the size of endorretnomas wirh advmcing gestation.

Resuho Twen‹y four parents with a total of 34 endorneriomas were iMuded in the ana is. All women we‹e managed expectantly during p«•gnancy. On the first ultrasound scan 29/34 (8SJ9s, 9S6 CI 734 - 97a) erdorretñomas appeared unilocubr with fne internal echoes ('ground glass' contents and they were p rly vaxu\arised on Doppler examination \/34 (ZPS 9S% CI 0.0 - 85) endometriorra was mu\tilocu\ar, with regular margins, 'ground glass' content and it was dso pools vascubiised. 4/34 (1 I.896, 956 CI 1.0 - 22.6) had sonographic features suggestive of decidudisation such as thick and irregular inner vyall, paplb y p ojections and highly vascular on Dopple examination. The endorre‹ñomas showed a endency to decrease in size during txegnancy.

Conclusions Pregnancy has a major effeci on rhe size and rro‹phobgical aprearar<es of ovarian end‹xnet›orrm Rapid regression of decidualised endometriomas is a helpful feature which could Le used to confirm tt¥•ir benign nature.

Keywords• Er›domWioma, Q'ciduallsation, Ovarian cyst Pregnancy

Background

The number nf women diagnosed with ovarian cysts dur- **ing pregnancy has increased in rocent years nla1nly due to the wide•pwad use uf ultrasound in the first ttimester. It lfas been reported that adriexal cuts can be seen on ultra- sound scan in 4. I% to 24.PM n£ pregnant women | I 2|.** Ovarian endometrinmas account for 4-5s of ovarian cysts diagnosed in early pregnancy |3]. The appears of endon\etrîomas un u)tmsound arv variable, ranging frum undocvlar cysts with low lewt eclums (ruurid giass' echogenicit7) |4,S] to si›lId tuuking ttimours {4-fi]. Despite the variabilité in their appearames rndömetriomas are relaôvely easy to classify correcdy tin iilm•xiiind examinaänn with the reported sensitivity arxl specificity being as high as 92'fi arif 97'fi respecôvety |43,7-9]. Hormonal change associated with the pregnancy *may* ause alterations \n the sonographic appearances of endometriomas which are referred to as decidualisation. Decidu lisation is the pr‹›cess uf en‹k›metrial change cauad by high pr‹›gcstemric levels which increnses glandular epithelial secretion, accumulation of glycogen and stromal vascularlty. Thèse changes create conditions which facilitatr implantation and development of early gestation. Formatiun ul ectopic decidua (de«iduwsîs) during pregnancy is a well-drx:umented phenumenun that is «aused by the +ffect t1f prugesterune un ec:t‹›pic endumetrium. such as Sri of endometriosis {IO]. Decidualised endomeLriomas may develop extensive inLraJumin«l Capillary projections with increased blood flow which are similar to malignant ovarian tumours | 1 I -J 3].

*1'he process cii decMualisatiun uI ovarian endunzerricma during pregnancy is well d‹<um<nt‹d. ATth‹›ugh the ultrasound f«stur«s of deciduati«otion can m1m\c ovarian can«er

’ConetQondbnce. davp.nrCoWc uÙhnh&ut
DepamnemofOOstmñc*ad ç4cxp. Unàærdry Co London
Ho*pmÆ. D3tEu«onftaŒtmdon hMVl 3BU. UR

Written by:
DR. WILLIAM HOO WEE LIAK
CONSULTANT OBSTETRICS & GYNAECOLOGY,
SUBSPECIALIST IN REPRODUCTIVE MEDICINE,
HOSPITAL KENSINGTON GREEN SPECIALIST CENTRE

MyENDOSIS

Persatuan MyEndosis

PPM - 018-10-26082014

There are many females who are affected by Endometriosis in Malaysia. Unfortunately there are limited documentation on these females.

Malaysians generally are not aware of what is Endometriosis and why do some women have this condition because it is often considered as a taboo subject. People here are quite uncomfortable speaking about menstrual health openly.

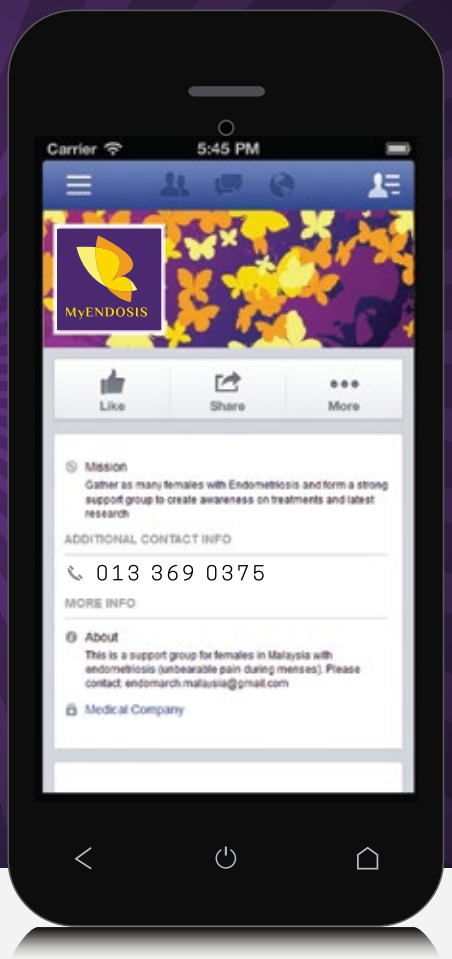

About Us

INTRODUCTION

Is is a known fact that Endometriosis impacts the physical, social and mental well being of females during their productive years(15-49 years of age). The main concern is that there is a delay before the average females with the disease are diagnosed.

In Malaysia, women are still struggling to be heard. People, in general, are still trying to understand this illness because women here are expected to bear the pain silently.

HISTORY

Persatuan MyEndosis was registered legally on 26 August 2014. Our group decided to address the issues of women suffering from Endometriosis.

Endometriosis is not just 'bad cramps', but it is actually a serious disease with severe medical consequences if left untreated.

Please help us end the silence on Endometriosis, so women in Malaysia can receive a proper diagnosis, quality medical care and hopefully one day, a much-needed cure.

OBJECTIVES

- To create awareness on Endometriosis
- To establish a cohesive relationship among patients & healthcare providers
- To develop positive reaction to healthcare treatment of Endometriosis
- To eliminate shame of addressing women's reproductive diseases

MyEndosis

endomarch_malaysia

endomarch.malaysia@gmail.com

013 369 0375

LUCRIN® DEPOT PDS

LEUPRORELIN ACETATE

3.75mg 1-Monthly, 11.25mg 3-Monthly, 30mg 6-Monthly

26 Years[1] and Counting

23/25 G Fine Needle
Less injection pain and discomfort[3]

DUAL Choice of SC/IM injection
For 1 and 3-monthly[7,8]
Sc for 6-monthly[9]

20 µg Microsphere Sustained-Release Technology
Maintains constant serum drug over 1, 3 and 6 months[4,5]

Prefilled, Dual-Chamber Syringe (PDS)[7,8,9]
NO external mixing required[2]
Reduce dosing and medication error[2]

80X Higher Potency than natural GNRH[6]
Persistent testosterone supression[4]

An Innovation Built to Last

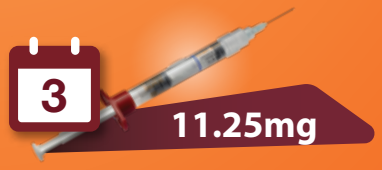

PDS – Prefilled Dual-chamber Syringe, SC – Subcutaneous, IM – Intramuscular

References: 1. Quest 3+, National Pharmaceutical Regulatory Agency (NPRA). https://quest3plus.bpfk.gov.my/pmo2/detail.php?type=product&id=MAL19950177ARZ. Accessed 19 May 2021. **2.** Makwana. S, et al. Prefilled syringes: An innovation in parenteral packaging. Int J Pharm Investig. 2011; 1(4): 200-206. **3.** Williams, G. et al. Randomised crossover trial to assess the tolerability of LHRH analogue administration. Prostate Cancer and Prostatic Dis. 2003; 6: 187-189. **4.** Tunn. UW et al. Comparison of LH-RH Analogue 1-Month Depot and 3-Month Depot by Their Hormone Levels and Pharmacokinetic Profile in Patients with Advanced Prostate Cancer. Urol Int. 1998; 60(1): 9-17. **5.** Tunn, U. W. and Wiedey, K. Safety and clinical efficacy of a new 6-month depot formulation of leuprorelin acetate in patients with prostate cancer in Europe. Prostate Cancer and Prostatic Dis. 2009; 12: 83-87. **6.** Abouelfadel, Z. et al. Leuprorelin depot injection: patient considerations in the management of prostatic cancer. Therapeutics and Clinical Risk Management. 2008; 4(2): 513-526. **7.** Lucrin 3.75mg local package insert, 2019. **8.** Lucrin 11.25mg local package insert, 2019. **9.** Lucrin 30mg local package insert, 2020.

Abridged Prescribing Information:

Lucrin 3.75mg
Composition: Leuprolide Acetate **Indications: Prostate Cancer:** Palliative treatment of advanced prostatic cancer, **Endometriosis:** Treatment of endometriosis for a period of 6 months. It can be used as sole therapy or as an adjunct to surgery, **Uterine Fibroids:** Treatment of anemia caused by uterine leiomyomata in woman who fail iron therapy, **Breast Cancer:** Treatment of breast cancer in premenopausal woman in whom hormone therapy is specified, **Paediatric use - Central Precocious Puberty (CPP)** Treatment of children with Central Precocious Puberty. **Dosage:** Depot inj 3.75 mg monthly. **Prostate Cancer:** In patients treated with GnRH analogues for prostate cancer, treatment is usually continued upon development of castration-resistant prostate cancer. Reference should be made to relevant guidelines. **Paediatric use - Central Precocious Puberty (CPP):** The recommended starting dose is 0.3 mg/kg for four weeks (minimum 7.5 mg). **Contraindication:** Known hypersensitivity to leuprorelin acetate, similar nonapeptides, or any of the excipients; Pregnancy **Special Precautions:** Changes in bone mineral density, Convulsion, Transient worsening of prostate cancer symptoms may occur during first few weeks of administration, i.e bone pain, spinal cord compression, Hyperglycemia, Increased risk of myocardial infection, stroke, effect on QT/QTc interval, Increase of sex steroids during early phase of therapy, Inadequate control of pubertal process due to non compliance or inadequate dosing, Not to be used by nursing mother. **Adverse Reactions:** prostate tumour flare, aggravation of prostate cancer, weight gain, weight loss, loss or decreased libido, increase libido, headache, muscular weakness, vasodilation, hot flushes, hypotension, orthostatic hypotension, dry skin, hyperhydrosis, rash, urticaria, hair growth abnormal, hair disorder, night sweats, hypotrichosis, pigmentation disorder, cold sweats, hirsutism, gynaecomastia, breast tenderness, erectile dysfunction, testicular pain, breast enlargement, breast pain, prostate pain, penile swelling, penis disorder, testis atrophy, mucosal dryness, diabetes melitus, glucose tolerance impaired, total cholesterol increased, LDL increased, triglycerides increased, osteoporosis, feeling hot, irritability, acne, eczema, nail disorder, vaginal discharge, genital discharge, vaginal hemorrhage, dysmenorrhea, menstrual disorder, breast atrophy, breast engorgement, metrorrhagia, menopausal symptoms, galactorrhea, dyspareunia, uterine disorder, vaginitis, menorrhagia, affects lability, rash including erythema multiforme, pain, injection site reactions including abscess **P/P: Depot inj 3.75 mg x 1's.**

Reference: PI dated Nov 2019 (CCDS03671019)

Lucrin 11.25mg
Composition: Leuprolide Acetate Indications: Prostate Cancer: Palliative treatment of advanced prostatic cancer, **Endometriosis:** Treatment of endometriosis for a period of 6months. It can be used as sole therapy or as an adjunct to surgery, **Uterine Fibroids:** Treatment of leiomyoma uteri (uterine fibroids) for a period up to 6 months. Therapy may be preoperative prior to myomectomy or hystrectomy, or it may provide symptomatic relief for the perimenopausal woman who does not desire surgery. **Breast Cancer:** Treatment of breast cancer in pre and peri-menopausal woman in whom hormone therapy is specified **Dosage:** Depot inj 11.25 mg every 3 months. **Prostate Cancer:** In patients treated with GnRH analogues for prostate cancer, treatment is usually continued upon development of castrationresistant prostate cancer. Reference should be made to relevant guidelines **Contraindication:** Known hypersensitivity to leuprorelin acetate, similar nonapeptides, or any of the excipients **Special Precautions:** Changes in bone mineral density, Convulsions, Transient worsening of prostate cancer symptoms may occur during first few weeks of administration, i.e bone pain, spinal cord compression, Hyperglycemia, Increased risk of myocardial infection, stroke, effect on QT/QTc interval, Increase of sex steroids during the early phase of treatment, Not to be used by nursing mother. **Adverse Reactions:** prostate tumour flare, aggravation of prostate cancer, weight gain, weight loss, loss or decreased libido, increase libido, headache, muscular weakness, vasodilation, hot flushes, hypotension, orthostatic hypotension, dry skin, hyperhydrosis, rash, urticaria, hair growth abnormal, hair disorder, night sweats, hypotrichosis, pigmentation disorder, cold sweat, hirsutism, gynaecomastia, breast tenderness, erectile dysfunction, testicular pain, breast enlargement, breast pain, prostate pain, penile swelling, penis disorder, testis atrophy, mucosal dryness, diabetes melitus, glucose tolerance impaired, total cholesterol increased, LDL increased, triglycerides increased, osteoporosis, feeling hot, irritability, acne, eczema, nail disorder, vaginal discharge, genital discharge, vaginal heamorrhage, dysmenorrhea, menstrual disorder, breast atrophy, breast engorgement, metrorrhagia, menopausal symptoms, galactorrhea, dyspareunia, uterine disorder, vaginitis, menorrhagia, affects lability. P/P: Depot inj 11.25 mg x 1's. *Please consult local full prescribing information before prescribing.*

Reference: PI dated Jan 2019 (CCDS03671017)

Lucrin 30mg
Composition: Leuprorelin Acetate Indications: Lucrin Depot for Injection is indicated in the palliative treatment of advanced prostatic cancer. **Dosage:** Depot inj 30 mg administered as a single subcutaneous injection every 6 months. **Contraindication:** Known hypersensitivity to leuprorelin acetate, similar nonapeptides, or any of the excipients; pregnancy and breastfeeding, women with undiagnosed vaginal bleeding. **Precautions:** Initially causes increase in serum levels of testosterone. Transient worsening of symptoms, or the occurrence of additional signs and symptoms of prostate cancer may occasionally develop during the first few weeks of Lucrin Depot for Injection treatment. Patients with metastatic vertebral lesions and/or urinary tract obstruction should be closely observed. reversible bone loss can occur with depot inj. Hyperglycaemia and increased risk of developing diabetes have been reported. Myocardial infarction, sudden cardiac death and stroke, QT prolongation, convulsions, effects on fertility have been observed. **Adverse Reactions:** Anaemia, increased appetite, libido decreased, heart failure, flushing, Acute pulmonary oedema , hyperhidrosis, erectile dysfunction, testicular atrophy, fatigues, injection site reaction, injection site inflammation, injection site pain, injection site induration, injection site erythema, injection site abscess, injection site swelling, transaminase increased. *Please consult local full prescribing information before prescribing.*

Reference: PI dated Aug 2020 (CCDS03671017)

abbvie

AbbVie Sdn Bhd (987315-T)
Level 9 Menara Lien Hoe, 8 Persiaran Tropicana 47410 Petaling Jaya, Selangor, Malaysia.
Tel: +603 7883 6888 Fax: +603 7883 6818

Full prescribing information is available upon request.
For Medical/Healthcare Professionals only.
AAll adverse event should be reported to drugsafety.pv@abbvie.com
MY-LUCR-210020 07092021

B|BRAUN
SHARING EXPERTISE

B. Braun Medical Supplies Sdn Bhd (Co. Reg. No. 56425-H)
Crown Penthouse, Plaza IBM | 8 First Avenue, Persiaran Bandar Utama | 47800 Petaling Jaya | Selangor, Malaysia
Customer Care Centre 1-800-88-8455 | Fax +603 7729 6715 | www.bbraun.com.my

Break the Endometriosis Cycle

with Visanne® targeted therapy for Endometriosis for[1-5]

- Early medical treatment
- Post-surgery to prevent recurrence
- When surgery is not possible or too difficult
- After Gn-RH analogue to prolong pain relief

REFERENCES: 1. Kohler G, et al. A dose-ranging study to determine the efficacy and safety of 1,2 and 4 mg of dienogest daily for endometriosis. Int J Gynaecol Obstet. 2010 Jan;108(1):21-5. **2.** Strowitzki T, et al. Dienogest is as effective as leuprolide acetate in treating the painful symptoms of endometriosis: a 24-week, randomized, multicentre, open-label trial. Hum Reprod. 2010 Mar;25(3):633-41. **3.** Kitawaki J, et al. Eur J Obstet Gynecol Reprod Bio. 2011 Aug;157(2):212-6. **4.** Morotti M, et al. Eur J Obstet Gynecol Reprod Biol. 2014 Dec;183:188-92. **5.** Imai A, et al. in Endometriosis - Basic Concepts and Current Research Trends, Prof Koel Chaudhury (Ed.), ISBN:978-953-51-052404, InTech.

ABBREVIATED PRESCRIBING INFORMATION **Brand name of product** Visanne 2 mg tablets (Dienogest). **Indications** Treatment of endometriosis. **Contraindications** Active venous thromboembolic disorder, past or present arterial & cardiovascular disease (eg myocardial infarction, cerebrovascular accident, ischemic heart disease); diabetes mellitus with vascular involvement; presence or history of severe hepatic disease & liver tumors; known or suspected sex hormone-dependent malignancies; undiagnosed vaginal bleeding. Pregnancy & lactation. Children prior to menarche. Hypersensitivity to the active substances or to any of the excipients. **Special warnings and special precautions for use** Serious uterine bleeding; Changes in bleeding pattern may occur; Circulatory disorders including those at risk of VTE; discontinue use if any symptoms of arterial or venous thrombotic events occur. Breast cancer, liver tumors. Osteoporosis. History of depression; Hypertension. Discontinue use upon recurrence of cholestatic jaundice &/or pruritus which occurred 1st during pregnancy or previous use of sex steroids, Diabetes Mellitus especially gestational diabetes mellitus, chloasma (especially chloasma gravidarium); Persistent ovarian follicles. Rare hereditary problems of galactose intolerance, Lapp lactose deficiency or glucose-galactose malabsorption. Regular physical & gynecological examination during use. Adolescents (menarche to 18 yr). **Undesirable effects** Common: Metabolism and nutrition disorders: weight increase, Psychiatric disorders: depressed mood, sleep disorder, nervousness, loss of libido, altered mood, Nervous system disorders: headache, migraine, Gastrointestinal disorders: nausea, abdominal pain, flatulence , abdominal distension, vomiting, Skin and subcutaneous tissue disorders: acne , alopecia, Musculoskeletal and connective tissue disorders: back pain, Reproductive system and breast disorders: breast discomfort, ovarian cyst, hot flushes, uterine / vaginal bleeding including spotting, General disorders and Administration site conditions: asthenic conditions, irritability. **For further prescribing information, please contact** Bayer Co. (Malaysia) Sdn Bhd B-19-1& B-19-2, The Ascent Paradigm, No. 1, Jalan SS7/26A, Kelana Jaya, 47301, Petaling Jaya, Selangor. Subject to medical prescription. **Date of text revision** 14.03.2016

Full prescribing information is available on request. For Healthcare Professionals Only.

Bayer Co. (Malaysia) Sdn Bhd
B-19-1 & B-19-2, The Ascent Paradigm, No. 1, Jalan SS 7/26A, Kelana Jaya,
47301 Petaling Jaya, Selangor, Malaysia.
Tel : +603 7801 3088 | Fax : +603 7886 3338 | Web : http://www.bayer.com

Visanne®
dienogest 2mg

PP-VIS-MY-0047-1 (11/19)

"Wow"

The clinical response most commonly heard when surgeons first experience the new **HARMONIC® HD 1000i.**

Designed for complex open and laparoscopic procedures, the new HARMONIC® HD 1000i provides:

Precision

Unique shape mimics a mechanical dissector*, reducing the need to use a separate dedicated dissecting instrument†

Strength

Unique blade design delivers consistent and reliable hemostasis‡ and can be used in challenging conditions

Efficiency

Increased sealing speed, multi-functionality, and simplified steps for use allow for optimal efficiency†§¶

ETHICON
PART OF THE Johnson & Johnson FAMILY OF COMPANIES
Shaping the future of surgery

The third-party trademarks used herein are the property of their respective owners.
054648-160610
© Ethicon Endo-Surgery, Inc. 2016

Johnson & Johnson Sdn. Bhd. (Co. No. 3718-D)

* Design Validation Study with surgeons (n=33) operating in simulated procedures in an animate porcine laboratory model. #051950-160425
† In a design validation study with surgeons (n=33) operating in simulated procedures in an animate porcine laboratory model (26/33) #053344-160516
‡ In a pre-clinical study, 100% (56/56) of porcine blood vessels remained hemostatic over a 30 day survival period. #049339-160315
§ In a porcine study comparing sealing times of HARMONIC ACE®+7 and HARMONIC® HD 1000i. HARMONIC® HD 1000i Shears transected vessels faster than HARMONIC ACE®+7 (mean vessel transection time of 9.186 vs 15.291). #051753-160420
¶ In a design validation study with surgeons (n=33) operating in simulated procedures in an animate porcine laboratory model (26/33) #053344-160516

0026-012018-MY

IMAGE1 S™ RUBINA™ – mORe to discover

The IMAGE1 S™ 4U RUBINA™ camera head combines 4K imaging technology with fluorescence imaging in the near infrared range for the display of indocyanine green (ICG). OPAL1® NIR/ICG technology and the marker indocyanine green (ICG) enable non-radioactive visualization of the entire lymph system surrounding a tumor in real time. The new Overlay, Monochromatic and Intensity Map image modes can provide additional information about the sentinel lymph node.

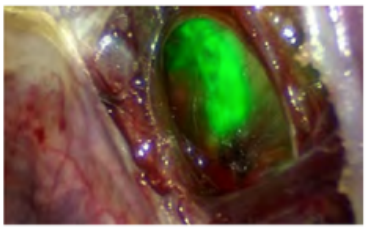
Overlay

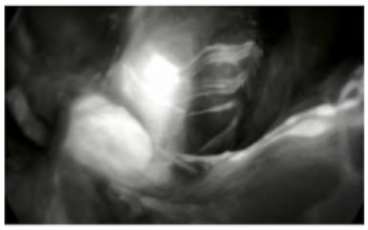
Monochromatic

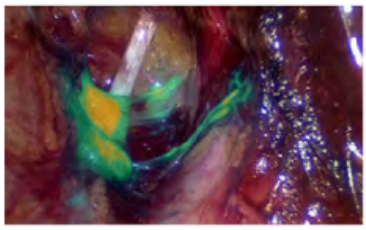
Intensity Map

STORZ
KARL STORZ — ENDOSKOPE

www.gotorubina.com

UMMI Surgical
making a Difference

Address : 10, Jalan Pendaftar U1/54,
Temasya Industrial Park, 40150 Shah Alam, Selangor
Company website : www.ummisurgical.com.my
Tel : 03-5569 6799
Contact : 012-248 5258
Email : grace@ummisurgical.com.my

PROUDLY SUPPORTED BY:

SILVER SPONSOR:

abbvie

BAYER

BRONZE SPONSOR:

B|BRAUN SHARING EXPERTISE

Johnson & Johnson

Medtronic

UMMI Surgical making a Difference

RegencySpecialistHospital | MahkotaMedical

www.regencyspecialist.com | www.mahkotamedical.com